

## **EFSUMB Course Book, 2nd Edition**

**Editor: Christoph F. Dietrich**

### **Basics in transthoracic echocardiography and standard documentation**

**Andreas Hagendorff, Stephan Stoebe**

<sup>1</sup>Department of Cardiology and Angiology, University of Leipzig

**Corresponding author:**

Prof. Dr. Andreas Hagendorff

Department of Cardiology and Angiology

University of Leipzig

04103 Leipzig, Germany

email: [Andreas.Hagendorff@medizin.uni-leipzig.de](mailto:Andreas.Hagendorff@medizin.uni-leipzig.de)

## Introduction

A special subdiscipline of sonography is echocardiography. The characteristics of echocardiography are the different features of the echocardiographic units and settings in comparison to other ultrasound machines, the orientation of sectional scan planes in relation to the coordinates of the axis of the left ventricle and the necessity of cardiologists to analyse the two-dimensional and colour-coded cineloops as well as the Doppler spectra to measure and calculate multiple parameters for the interpretation of the cardiovascular state of the patient. These findings have to be directly integrated into the current diagnostic and therapeutic scenarios. The scenario of practical echocardiography requires - especially in emergency settings - the necessity of clinical experience of cardiovascular disorders and diseases and the knowledge about pathophysiological alterations and their effects on cardiovascular function with the prerequisite of adequate technical skills of the method.

The consequence of this complex situation is the fact that there are different opinions how to perform and to teach echocardiography. On the one hand there are one day courses, internet education and other short-term procedures promising the complete learning and understanding of echocardiography, on the other hand there are concepts of long-term educational procedures with theoretical courses and practical traineeships. These differences can be explained by the majority view of different medical faculties being concerned with echocardiography like cardiologists, cardiac surgeons, anesthesiologists, emergency medicine specialists, general practitioners and sonographers.

If echocardiography is only considered as a method which enables the user to detect basic entities like "the heart is beating", "the heart function seems to be normal", "the right heart seems to be enlarged", "there are turbulences at the heart valves", "there is some fluid around the heart" or "there are some hints for hypervolemia", echocardiography can be very helpful in emergency situations, but this simple attitude to perform echocardiography will endanger the technique and will be detrimental to communicate the potentials of this method - especially with respect to the modern features.

Thus, echocardiography has to be taught with caution and in detail to enable the users to become familiar with all options of this method in order to use its potentials correctly. Scanning is only the methodological aspect, being entitled to acquire the images with the optimal image quality is more than methodology, it is something like art. With respect to the

diagnostic challenges it should not be the goal to produce just any image by echocardiography. It should be mandatory to accomplish the goal of producing the best images in terms of accuracy of the visible cardiovascular structures and in terms of standardisation of imaging. Standardisation is the prerequisite - especially if measurements and calculations are based on images - for minimising observer variability and for reliable comparisons of the documentations in follow-up investigations [(1;2)].

The following chapter will introduce the reader on how to get a structured approach and an artistic disposition into the technical understanding of the basics in transthoracic echocardiography.

## Principles

The learning of a new technical method like echocardiography starts with the instruction of handling the instrument. It is like trying to play a new music instrument. Thus, the hand position of the transducer and the handling of the transducer are essential for acquiring good images in echocardiography.

The first principle of scanning is to get the feeling for the corresponding scan plane. The scan plane has to be automatically implemented into the coordination of handling the transducer and the arrangement of cardiac structures on the monitor. This eye-brain-hand interaction is essential for making important corrections of the transducer position for adjusting the correct view. In practice, one defined sectional plane of the heart - and this sectional plane is the long axis view of the left ventricle - has to be coordinated with a certain hand position of the transducer to get a starting or home position for the following echocardiographic investigation. The second important principle is the stereotactic mode of scanning. To be able to visualise the cardiac structures well-aimed, the transducer position has to be altered only in one single plane of space. That implies that the transducer has to be tilted towards the short edge of the transducer without flipping towards the long edge of the transducer and without rotating the transducer - or has to be flipped towards the long edge of the transducer without tilting towards the short edge of the transducer and without rotating the transducer - or has to be rotated without tilting and flipping the transducer. Using these two

principles the scanning procedure can be systematically performed in an objectively guided and highly standardised approach.

### **The standardised transthoracic investigation**

The transthoracic echocardiographic approach to the heart is enabled by different acoustic windows. In left lateral position of the patient the left parasternal acoustic window is located near the anterior mid-clavicular line normally between the third and fifth intercostal space. The apical acoustic window is lateral at the left lower costal arch directly above the apex of the left ventricle. In supine position of the patient the subcostal window is directly below the xiphoid process and the suprasternal window is directly at the jugulum. In rare conditions, e.g. for diagnosis of aortic valve stenosis the right parasternal acoustic window can be helpful. It is located in extreme right lateral position near the right sternal border between the first and second intercostal space.

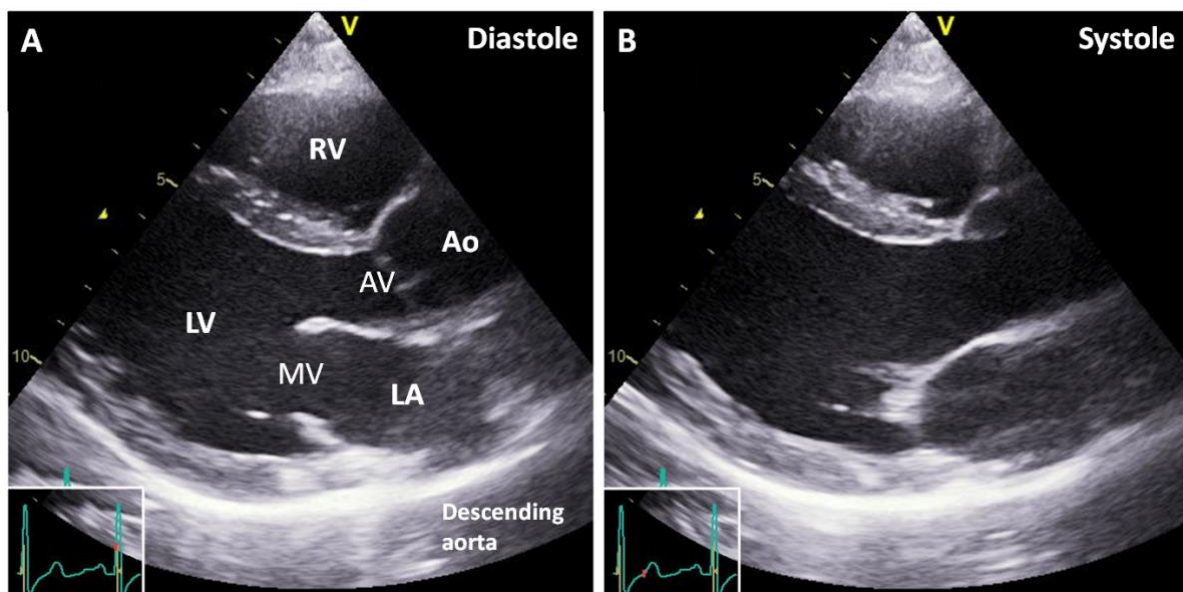
The standardised echocardiographic views are characterised by specific cardiac structures and their arrangement in the scanning sector.

### **The documentation taking the left parasternal acoustic window as the starting point**

The first and the most important view for the orientation of the transducer position and the handling as well as the understanding of the individual coordinates of the heart is the parasternal long axis view. This view is characterised by the centre of the mitral valve, the centre of the aortic valve and the left ventricular apex. Because the tip of the left ventricular cavity cannot be visualised from the left parasternal window the correct sectional plane in the centre of the left ventricular cavity is documented by the anteroseptal and posterior midbasal left ventricular wall arranged in parallel without the intersection of papillary muscles during diastole and systole. In addition, the free right ventricular wall, the section of the right ventricular outflow tract, the aortic root and the proximal part of the ascending aorta and the cross section of the descending aorta is visualised. The standardised parasternal long axis view is additionally characterised by the arrangement of the heart in the sector. The ventral border of the mid anteroseptal left ventricular wall at the left side of

the sector and the ventral border of the ascending aorta at the right side of the sector have to be in a horizontal line if the mitral valve is centred in the sector [Figure 1].

**Figure 1** The standardised parasternal long axis view is characterised by the following cardiac structures: the free right ventricular wall near to the transducer in front of the right ventricular cavity (RV), the basal and mid anteroseptal region of the left ventricle (LV), the left ventricular cavity in the long axis, the basal and mid posterior region of the left ventricle, the mitral valve (MV) sliced in the centre of the valve annulus, the aortic valve (AV) sliced in the centre of the valve annulus, the long axis of the initial portion of the aortic root and the ascending aorta (Ao), the longitudinal section of the left atrium (LA) and a cross section of the descending aorta at the far side of the left atrium. In (A) the parasternal long axis view is shown during late diastole, in (B) during mid systole.



By an isolated clockwise 90° rotation of the transducer short axis views of the left ventricle will be obtained. The caudal short axis view of the left ventricle illustrates the main bundles of the papillary muscles as well as the anteroseptal, anterior, lateral, posterior, inferior and inferoseptal regions of the left ventricle (clockwise starting with the ventral region). With cranial flipping towards the long edge of the transducer the chords of the mitral valve, the

mitral valve itself, the interatrial septum and the cross section of the left ventricular outflow tract, the aortic valve annulus and at least the long axis view of the pulmonary trunk is visualised. The documentation of a cine loop of the left ventricle with the papillary muscles, the mitral valve as well as the aortic valve is mandatory according to the European standard of documentation. A suitable approach for a standardised documentation of all short axis cine loops is the acquisition of a standardised M-Mode sweep [Figure 2] during 8-12 cardiac cycles with the possibility of analysing the complete two-dimensional cine loops by post-processing. The M-Mode sweep acquisition using the short axis views displays the correct cursor position through the centre of the left ventricle as well as the correct transducer position during the acquisition by a horizontal line between the ventral border of the mid anteroseptal left ventricular wall and the ventral border of the ascending aorta. Thus, correct measurements of wall thickness and cavity dimensions of the left ventricle can be performed. Oblique cuts and secants can be avoided by a correct M-Mode sweep documentation.

**PREVIEW CHAPTER ONLY FOR THE REMAINING 100 PAGES PLEASE PURCHASE THE FULL CHAPTER.** You can purchase the full chapter for just 2.99 GBP by clicking on the link below and completing your purchase on the Secure PayPal server.

